



# NATIONAL VETERINARY LABORATORY

P.O. Box 239, 1Tice Road  
Franklin Lakes, NJ 07417  
877-NVL-LABS (877-685-5227)  
[www.natvetlab.com](http://www.natvetlab.com)

## NEWSLETTER

### Feline *Bartonella* Test Results and More Public Health Implications<sup>©</sup>

Evelyn E. Zuckerman, Editor

Winter 2004

Vol. 3, Number 1

#### In This Issue:

In the winter 2004 issue of the NVL Newsletter we will summarize our *Bartonella* test results to date and give several more examples of public health risks to cat owners and veterinarians. A Gallup survey shows that most pet cats in the United States are adopted strays, a risk factor that doubles the likelihood for *Bartonella* infection. *Bartonella* testing of all cats is becoming routine in many practices.

#### *Bartonella* Test Results

We have performed 35,684 FeBart<sup>®</sup> *Bartonella* tests between November 1999 and December 31, 2003. The following tables summarize our findings. *Bartonella* infection is widespread in pet cats.

#### *Bartonella* Pathogenesis

*Bartonella* have a strong tendency to adhere to endothelial cells which leads to the wide and varied tissue pathogenesis observed in cats, dogs, and people.

#### FeBart<sup>®</sup> Test:

During our 5-year development of an accurate serological test for *Bartonella* infection we compared IFA, ELISA and western blot (WB) tests and found the WB to be the most accurate. The data in the following tables are from the FeBart<sup>®</sup> WB test. To date we have tested 35,684 cats, 333 dogs, 5 horses, 5 cougars, 2 lions and 1 serval. Forty-five percent of the cats tested were positive, the majority of which were cats that had chronic inflammatory diseases. The percent of cats infected with *Bartonella* appears to be constant with the increased numbers tested (Table 1). The occurrence of *Bartonella* in dogs will be the subject of a future Newsletter.

Table 1 FeBart<sup>®</sup> Tests of Cats to 12-31-2003

Cats	# Tested	# Infected	% Infected
Healthy*	9,704	3,714	38%
Disease	25,980	12,255	47%
<b>Totals:</b>	<b>35,684</b>	<b>15,969</b>	<b>45%</b>

\* Many with infection risk factors

Approximately 50% of cats with inflammatory diseases in various organ systems test positive and are infected with *Bartonella* (Table 1). A positive test may indicate: 1) that *Bartonella* is the sole etiological agent for the disease, 2) that

*Bartonella* is a co-etiological agent for the disease, 3) that *Bartonella* is not causing the disease but is infecting the cat. In the following table, the infection rate in cats with inflammatory diseases is compared to the base-line infection rate in **healthy cats with no reported *Bartonella* infection risk factors (X)**.

Table 2 *Bartonella*-Infection: Cats\* with Inflammatory Diseases

Diseases	No. Tested	No. Infected	% Infected	Difference / X
<b>Healthy: No Risk Factors</b>	<b>840</b>	<b>170</b>	<b>20%</b>	<b>X</b>
Oral Disease	19,823	9,932	50%	2.5X
Resp. Diseases	4,933	2,471	50%	2.5X
Ocular Diseases	3,767	1,820	48%	2.4X
GI Diseases	1,522	747	49%	2.5X
Skin Diseases	399	211	53%	2.7X
Other Bart. Diseases	2,534	1,216	48%	2.4X
<b>Total</b>	<b>32,978</b>	<b>16,397</b>	<b>50%</b>	<b>2.5X</b>

\* Many cats had multiple inflammatory diseases, thus totals in Table 2 exceed the total number of cats tested.

#### Human *Bartonella* Diseases

We have investigated numerous additional cases of feline *Bartonella*-induced human diseases during the past 6 months. The following are descriptions of the cases and the associated cats.

##### Case 1: Veterinarian: Cat Scratch Disease

A 34-year-old female veterinarian practicing in the New York City metropolitan area was diagnosed with Lyme disease 13 years earlier. In March of 2003 she began to have severe headaches, fevers, enlarged lymph nodes and a stiff neck. She consulted a local physician who treated her with antibiotics which did not alleviate her symptoms. After again seeing her physician she was told to "get married and go on a vacation." With that recommendation in mind she consulted an infectious disease specialist at a major medical center who was suspicious of *Bartonella* infection and cat scratch disease, even though there was no history of a cat scratch or bite. Her *Bartonella* antibody test was positive for *Bartonella quintana*. *Bartonella quintana* has not yet been isolated from cats but is likely to be an additional *Bartonella species* capable of infecting pet cats. She was treated with azithromycin for 3 weeks and her

symptoms promptly resolved within the first 2 weeks of therapy. We tested her serum by WB and found her to be more reactive to *Bartonella henselae* than to *Bartonella quintana*. The doctor remains healthy, happy and single!

##### Case 2: Chorioretinitis

A 56-year-old grandmother living in Texas adopted a stray kitten 2 years after completing chemotherapy for breast cancer. Several weeks later she, and her grandchildren, developed a flu-like illness with fever, chills and aches. The children rapidly improved but the grandmother developed tender lymph nodes under both sides of her jaw and a persistent fever of 103-104°F. She was treated with azithromycin for 3 days but did not improve. Two weeks later a "fog" developed in her left eye that progressed into very blurred vision. An infectious disease specialist then submitted serology for *Bartonella* that was highly positive (1:1024). She was again treated, not with azithromycin, but her vision did not improve. Two weeks later she developed muscle and joint pain but was still not treated specifically for *Bartonella*. After her kitten tested +4 strongly *Bartonella* positive and after consulting her veterinarian, Dr. Stanley Zbylot, Spring Creek Animal Hospital, Tomball, Texas, the woman returned to her physician, with our *Bartonella* brochure in hand, and strongly requested azithromycin treatment for 21 days. Her physician agreed and the clinical improvement was rapid and dramatic, her muscle and joint pain resolved and her blurred vision improved by about 70%. However, there appears to be some permanent loss of vision due to retinal scarring.

Her ophthalmologist advised her "to get rid of the kitten." We reassured her that this was not necessary and the kitten has been treated with azithromycin for 21 days.

This case illustrates that some people may be more susceptible to *Bartonella* infection due to the immunosuppressive effects of chemotherapy. It is important for veterinarians to inform cat owners about *Bartonella*, especially people adopting stray kittens, and any member of the household who is immunosuppressed due to chemotherapy, an organ transplant or HIV infection. It also illustrates the need for a prompt diagnosis and appropriate effective long-term specific antibiotic therapy for *Bartonella* in order to avoid retinal scarring. Eye disease is common

in people infected with *Bartonella* and there are numerous publications concerning *Bartonella*-induced eye diseases in humans (see references in our laboratory notes)<sup>1-4</sup>. Table 3 summarizes our *Bartonella* test results for cats being tested due to public health concerns.

**Table 3**  
**Public Health Reasons for Testing**  
**Cats for *Bartonella***

Concern	No. Tested	No. Infected	% Infected
Cat Scratch Disease- house	337	215	64%
Immunosuppressed person	35	12	34%
Organ transplant	38	15	40%
Chemotherapy	27	10	37%
HIV infection	6	4	67%
Children in house	77	30	39%
Cat going to nursing home	16	7	44%
<b>Totals:</b>	<b>536</b>	<b>293</b>	<b>55%</b>

### Case 3: Meningoencephalitis & Chorioretinitis

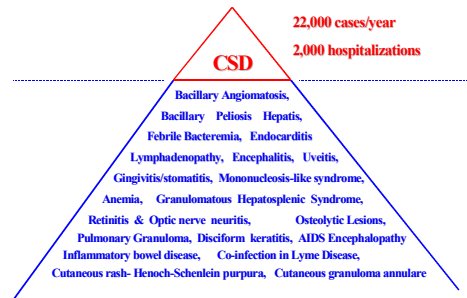
The Pennsylvania family of a 42 year-old woman with a 2.5 year-old cat adopted a 4-week-old stray barn kitten with fleas. The kitten was treated for the flea infestation and was otherwise healthy. Six months later the kitten jumped off the woman's lap leaving a slight scratch on the left knee with a hind claw. Two weeks later a red papule developed at the site followed a week later by lymphadenopathy of the left inguinal lymph nodes, a persistent fever of 101.5°F, and headaches. The woman's mother, a retired nurse living in Florida, diagnosed the condition by telephone as cat scratch disease (CSD). Her physician apparently did not include CSD in his differential diagnosis and gave her a short course of antibiotics (not azithromycin or doxycycline) with no improvement.

A week later she was seen at her local hospital where a clinical diagnosis of CSD was made and she was treated with azithromycin for 5 days (Editorial Comment: not long enough). Shortly after completing treatment the woman had grand mal seizures and was flown to a regional referral hospital where a brain MRI was within normal limits. A PCR on the CSF was negative for *Bartonella*, but her serology for *Bartonella* was positive. She lapsed into a coma for 3 days, was placed on a respirator, and was given intravenous azithromycin, doxycycline and rifampin combination for 5 days (rifampin and doxycycline pass through the blood brain barrier). She recovered rapidly and fully and walked out of the hospital on the 6<sup>th</sup> day. She was treated with oral azithromycin for an additional 21 days and remains healthy.

This case illustrates the lack of awareness among some physicians of the diverse nature of the clinical signs of *Bartonella* infection in their patients and the rapid response to the appropriate antibiotic therapy<sup>1-4</sup>. The clinical syndrome of CSD is only the "tip of the iceberg" of *Bartonella* diseases (Figure 1). The kitten and the adult cat in this household were both +4 strongly *Bartonella* positive. We thank Antech Diagnostics for assisting us in contacting the referring veterinarian in this case.

**Figure 1**

## Cat Scratch Disease: The Tip of the *Bartonella* Iceberg



### Case 4: Veterinary Office- Group-Test

Four members of a veterinary office in the New York Metropolitan area asked to be tested for *Bartonella* for research purposes. The 2 veterinarians were healthy, an office manager reported periodic fevers of unknown origin, and a veterinary technician complained of persistent low-grade fevers and a chronic condition. We found 1 of the healthy veterinarians and the veterinary technician to be serologically positive. Although healthy, the veterinarian was one of the strongest human WB reactors that we have detected. He remains healthy, without treatment, 6 months after the test. The veterinary technician was negative by a licensed human *Bartonella* test. A recent study from Japan found that approximately 4% of veterinary technicians, working 5 years or longer, had acquired cat scratch disease.<sup>5</sup>

### Case 5: Mononucleosis-like Syndrome<sup>6</sup>

An 18 year-old girl living in Florida was scratched by a neighbor's 8-week-old stray kitten. Seven weeks later she developed a mononucleosis-like syndrome, fever, and fatigue, followed by loss of vision in one eye.<sup>6</sup> Optic neuritis was diagnosed and a serological test for *Bartonella* was recommended by an ophthalmologist due to a swollen optic nerve and characteristic retinal lipid exudates that form a macular star. She was hospitalized due to severe headaches and meningitis but has recovered completely 6 weeks after therapy. Her serological test was positive for *Bartonella henselae* and the kitten was a strong +4 *Bartonella* positive.

### Case 6: Pulmonary Infiltrates- Pneumonia

After receiving our *Bartonella* laboratory notes and Newsletters, Dr. Carl Myers from Theodore Veterinary Hospital, Theodore, Alabama thought of a client who runs a cat rescue home (>100 cats) who has had numerous cats with chronic inflammatory diseases. One particular cat, with intractable URI for 14 months, came to mind and he called the owner to come in with the cat for a *Bartonella* test. The 47 year-old woman had been treating the cat for the past 14 months and was often scratched and bitten while treating the cat. The cat tested positive for *Bartonella* and Dr. Myers instituted azithromycin therapy, which totally resolved the longstanding URI. During the clinic visit the woman mentioned that she also developed chronic respiratory disease, "like her cat," that was also refractory to antibiotic therapy. During the 14 months of her respiratory illness she had radiological evidence of pulmonary infiltrates and had been tested for many agents including HIV

and TB. All tests were negative. Her illness became so severe that she required the use of an oxygen machine for more than 6 months. She also reported chronic headaches and blurred vision.

After hearing this, Dr. Myers urged his client to take our *Bartonella* Cat Owner brochure to her physician and insist that a *Bartonella* test be done. Her physician was convinced and submitted a *Bartonella* serological test, which proved to be "inconclusive." However, her physician thought that she may be infected with *Bartonella* and instituted doxycycline therapy for 21 days. There was a dramatic improvement in her condition within 10 days of the start of therapy. Her breathing became normal; she did not require an oxygen machine, and her headaches resolved. In obtaining the information for this Newsletter the woman mentioned that her 13 year-old son has also been chronically ill with fevers and persistent headaches. We urged her to consult the boy's physician regarding the possibility of *Bartonella* infection.

This case again illustrates the diverse nature of *Bartonella* clinical symptoms in people and the fact that *Bartonella* is "below the radar" of many physicians due to the diverse clinical presentations. However, with this patient's association with numerous stray cats, *Bartonella* should have been a primary consideration.

### Editor's Note:

We are often asked if people living in households with *Bartonella* infected cats, or veterinarians and their employees, should be tested or treated for *Bartonella*. Some have asked if veterinarians and veterinary technicians should be tested yearly or bi-yearly. We recommend that healthy people need not be tested or treated. However, persons with chronic conditions, any of those listed in Figure 1, should consult their physicians with the information that they have been exposed to a *Bartonella* infected cat. It is important that the physician truly consider *Bartonella* as a possible cause for the illness and it may be necessary to insist that they consider this organism as occurred in **Case Reports 1, 2, 3, and 6**. We thank Dr. Donald DeForge, Silver Sands Veterinary Center, and Milford CT for calling our attention to these questions.

### References:

- Ormerod LD, Dailey JP. Ocular manifestations of cat-scratch disease. *Curr Opin Ophthalmol*. 1999; 10: 209-16.
- Rosen B. Management of *B. henselae* neuroretinitis in cat-scratch disease. *Ophthalmology*. 1999; 106: 1-2.
- McGrath N, et al. Neuroretinitis and encephalopathy due to *Bartonella henselae* infection. *Aust N Z J Med*. 1997; 27: 454.
- Noah, DL., et al. Cluster of five children with acute encephalopathy associated with cat-scratch disease in south Florida. *Pediatr Infect Dis J*. 1995; 14: 866-9.
- Asano K, et al. Risk of acquiring zoonoses by the staff of companion-animal hospitals. *Kansenshogaku Zasshi*. 77: 944-947, 2003.
- F Massei, et al. Pseudoinfectious mononucleosis: a presentation of *Bartonella henselae* infection. *Arch Dis Child*. 83: 443-444, 2000.

*Bartonella* references can be obtained at:

[www.nlm.nih.gov/](http://www.nlm.nih.gov/)