

# NATIONAL VETERINARY LABORATORY

P.O. Box 239, 1Tice Road  
Franklin Lakes, NJ 07417  
877-NVL-LABS (877-685-5227)

[www.natvetlab.com](http://www.natvetlab.com)

## NEWSLETTER

### Feline *Bartonella*:

### Public Health Implications: Lessons Learned From Case Histories<sup>©</sup>

Evelyn E. Zuckerman, Editor

Winter 2006

Vol. 5, Number 1

#### In This Issue:

In the Winter 2006 issue of the NVL Newsletter we will cover the lessons learned from case histories of human *Bartonella* diseases caused by feline *Bartonella*. Feline *Bartonella* pose the greatest threat to human health since cats live in the most intimate relationship to humans than any other *Bartonella* reservoir host animal.

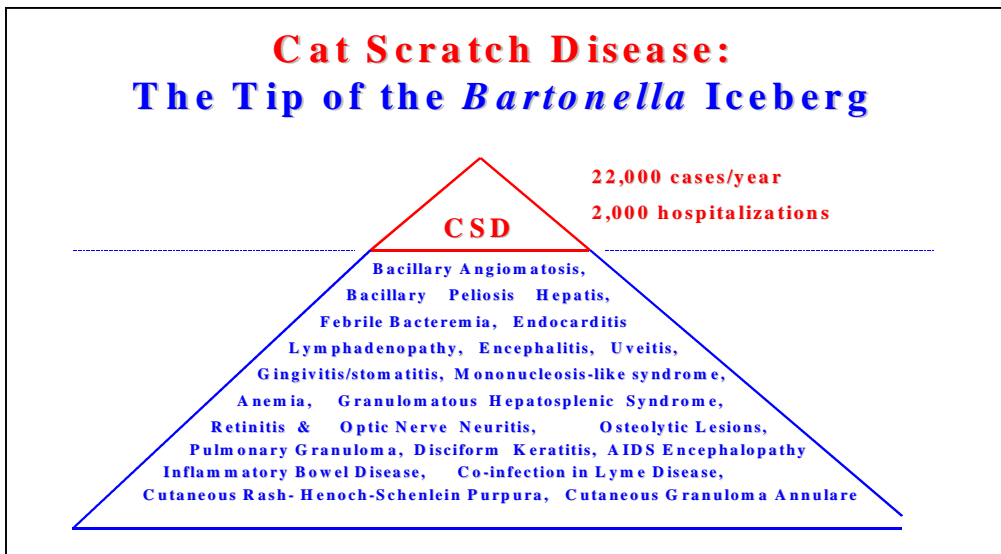
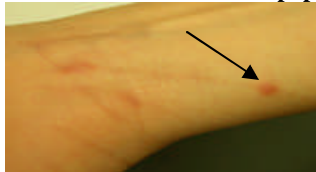#### Human *Bartonella* Diseases Occurring in Households with *Bartonella* Infected Cats:

For the past 5 years this laboratory, with the collaboration of many practitioners, has investigated cases of human *Bartonella* diseases in households where we tested cats. As we have previously described in our Newsletters, cat scratch disease (CSD) is only the "tip of the *Bartonella* disease iceberg." Many serious *Bartonella* diseases occur with or without the classical CSD prodrome. The diseases seen below the surface of CSD in the iceberg figure occur far more often than most veterinarians or physicians realize. We have investigated the following cases:

#### 1. Classical CSD "Prodrome" in the Wife of a Veterinarian:

The wife of a veterinarian, who handled many *Bartonella*-infected cats, was scratched by a client's cat. Although she immediately disinfected the wound, several days later a classic papule developed in one of the scratches (see figure below). The veterinarian was very aware of *Bartonella* and was testing most cats seen in the practice. Despite reluctance by her physician, he insisted that his wife be treated with azithromycin for 3 weeks. The lesion resolved in several weeks and no lymphadenopathy or severe disease sequelae occurred. The *Bartonella* antibody titer decreased 8 fold after therapy by our research human titration test. There was no disability and the cost was less than \$250 due to the awareness of the human *Bartonella* symptoms.

*Bartonella* CSD "Prodrome" papule



#### 2. Chronic Fatigue Syndrome with Co-infection with *Borrelia* (Lyme):

A 16-year old boy living in New York State developed a left eyelid droop in September 2004. He lived with an 11-year old *Bartonella* infected DSH cat, obtained years before as a stray. The family's veterinarian never discussed *Bartonella* with the family over the years. Although no fleas were seen on the cat, the family had found ticks on the cat several times. The cat was also serologically positive for *Borrelia burgdorferi*. The boy developed headaches, extreme fatigue, joint pain, conjunctivitis and was doing poorly in school. In January 2005 he developed a painful, enlarged lymph node behind his left ear. He was seen by the following doctors: 1) a pediatrician, 2) a local neuro-ophthalmologist, 3) a neuro-ophthalmologist at Harvard, 4) an infectious disease specialist, 5) a neurologist, 6) a family practitioner and 7) a specialist in tick borne diseases. An initial diagnosis of myasthenia gravis was later discarded. At the urging of the boy's mother, who consulted a Lyme disease support group and did extensive research on the Internet, a *Bartonella* antibody test was performed. The IgG titer was positive at 1:128, but the infectious disease specialist interpreted the result as "borderline," and did not treat with antibiotics.

Over the 6-month duration of the illness the boy was hospitalized for various periods: had an MRI and a CAT scan, blood culture, was treated with

several antibiotics, and had a PIC line inserted for 3 weeks of therapy. Finally, the 7<sup>th</sup> physician, the specialist in tick borne diseases, suggested the diagnosis of atypical *Bartonella* infection (CSD) and the boy was treated with azithromycin for several weeks. The boy slowly made a full recovery. The illness caused disability for 6 months and cost more than \$40,000 in medical bills.

#### 3. Which of these cats made a 12-inch wound in the chest of a 50-year-old man?

Answer on back of this page.

Lion



Cougar



Cheetah



Miss Kitty, DSH

## Answer: Miss Kitty



### 3. Vegetative Aortic Valvulitis:

Yes, Miss Kitty, a 6-pound, 6 month-old, *Bartonella* infected female DSH stray kitten, caused a 12-inch thoracic wound by a playful scratch months earlier. That scratch transmitted *Bartonella henselae* to a 51-year-old immunocompetent man, which resulted in a clinical syndrome that ended in open-heart surgery (12" thoracic incision) to replace the aortic valve due to *Bartonella henselae*-induced vegetative valvulitis.

It all started when a cute 3-month-old stray was brought into the house after a trip to the veterinarian for worming, vaccinations and flea medication. At that visit, the veterinarian made no mention of the possible public health danger of *Bartonella* from stray kittens, and after this general excellent health assessment, the kitten became a member of the household. Although the kitten was playful, there was no known significant scratch or bite noted. Three months after the kitten came into the household the owner developed persistent fever, headache, general weakness, clubbing of his fingers, severe leg cramps, and night sweats that persisted for weeks. Right axillary lymphadenopathy (CSD prodrome) occurred several weeks later. After examinations by several physicians, the patient was referred to a rheumatologist for the leg cramps. The rheumatologist heard a heart murmur and asked the patient if he owned a cat. The patient was diagnosed with *Bartonella* infection by serology and referred to a cardiologist.

After several cardiac diagnostic tests, a diagnosis of culture-negative aortic valve vegetative valvulitis was made. The patient was referred to a world famous clinic for aortic valve replacement. The removed valve was analyzed and found to contain *Bartonella henselae* in the vegetative lesion. The illness caused 6 months of disability and cost more than \$150,000 in medical bills. One wonders what would have happened had the veterinarian recommended *Bartonella* testing at the time of the kitten's first health exam. However, it should be noted that most veterinarians do not discuss the public health aspects of feline *Bartonella* with their clients. *Bartonella*-induced endocarditis and valvulitis is a severe sequelae of the "CSD" syndrome.<sup>1,2</sup>

### 4. Veterinary Technician- Chronic Fatigue Syndrome:

A veterinarian received a call from a colleague asking if he had a technician available to work in his hospital since his technician was very sick with persistent fever, headaches, and severe fatigue. The technician thought that she had chronic fatigue syndrome. The veterinarian

remembered our human *Bartonella* iceberg figure and suggested to his colleague that the sick technician have a *Bartonella* test. She had to convince her physician, but the *Bartonella* test was performed and the result was positive. The technician made a full recovery after appropriate antibiotic therapy. The duration of illness was 6 weeks and cost about \$500.

### 5. Atypical CSD Syndrome in a Child Presenting as Deep Neck Space Infection:

A 4-year old boy, living with 2 adult cats, developed a sore throat, fever of 103° F, and a large swelling on the right side of his face, about 2 inches below his ear. He complained of muscle and joint pain. His illness persisted for 3 weeks and the family's pediatrician referred the child to ENT specialists at a large University Hospital. The boy was hospitalized and quarantined for some time. The swelling was surgically drained, once from the side of the face and twice in the throat near the tonsils. Dye contrast CT scans were performed 3 times. After 5 weeks the child was referred to an infectious disease physician, who diagnosed CSD clinically and performed a *Bartonella* serology, which was positive. The boy was treated with the appropriate antibiotics and made a full recovery. Although there was no history of a cat bite or scratch from the family's pet cats, 1 of the 2 cats tested positive for *Bartonella*. The duration of the illness was 8 weeks and cost the family (insurance) more than \$80,000. Deep neck space infections are atypical severe sequelae in 7% of CSD cases.<sup>3</sup>

#### Lessons From These Case Histories:

1) Physicians do not know much about atypical *Bartonella* diseases in their patients; 2) Those physicians that do know of *Bartonella* diseases feel that treatment need only be given for a few days; 3) Incorrect or delayed diagnosis of a *Bartonella* disease can be life-threatening or result in severe sequelae; 4) *Bartonella* diseases can be financially costly<sup>4</sup>; 5) Most veterinarians DO NOT discuss the public health risks of feline *Bartonella* with their cat owning clients.

### Recent *Bartonella* Publications:

#### CSD Hospitalizations in Children in the United States<sup>4</sup>:

Reynolds and colleagues from the CDC and the Department of Health and Human Service studied the occurrence of CSD in children under 18 years old in 2000<sup>4</sup>. They estimated that 437 cases of CSD in children required hospitalization. Of those children hospitalized for CSD, 24% were atypical presentations with 12% neurologic complications, 7% involvement of organs (liver/spleen), and 5% other presentations. The average hospitalization cost for CSD cases in children was \$6,140 and total annual hospitalization charges were approximately \$3.5 million. They concluded that childhood cases of CSD requiring hospitalizations did not increase in 2000 compared to previous estimates in the 1980s, despite significant increases in cat ownership in the intervening time.

#### *Bartonella* Found in House Dust Mites<sup>5</sup>:

Valerio and colleagues recently reported that house dust mites were infected with *Bartonella* and other Gram-negative bacteria.<sup>5</sup> These Gram-negative bacteria are probably the source of endotoxin that is found in mite allergenic extracts. The *Bartonella* species detected were *B. henselae* (cat & dog), *B. quintana* (human & cat), *B. vinsonii* (dog) and *B. grahamii* (woodland rodents). It is not known if house dust mites transmit *Bartonella* among animals or people.

#### *Bartonella quintana* Found in Cats<sup>6</sup>:

La and colleagues have recently found *B. quintana* for the first time in pet cats<sup>6</sup>. Until this observation, *B. quintana* was thought to be a human *Bartonella*, restricted to humans, and to be transmitted only by the human body louse *Pediculus humanus corporis*. *B. quintana* appears to have originated from *B. henselae*, the prototypic feline *Bartonella* spp., through the loss of several important genes. This now expands the known feline *Bartonella* to six species. Of interest, both *B. henselae* and *B. quintana* were found in the dental pulp of cats.

#### *Bartonella* Helped to Defeat Napoleon's Army in 1812<sup>7,8</sup>:

The 1812 invasion of Russia by Napoleon is one of the worst military defeats in history. Only about 25,000 of the 500,000 soldiers sent toward Moscow survived. Many of these lice-infested soldiers died of febrile diseases, not in combat. In a fascinating recent article published in The Journal of Infectious Diseases, Dr. Didier Raoult and his colleagues found that roughly 3,000 of Napoleon's soldiers, found in a mass grave in Vilnius, Lithuania, were killed by lice-borne diseases such as trench fever (*Bartonella quintana*) and typhus.<sup>7</sup> A recent finding concluded that *Bartonella quintana* was derived from the feline *Bartonella*, *Bartonella henselae*, through the loss of 18% of the genome and genomic islands (bacteriophage regions), and thus genome mobility.<sup>8</sup> Remnants of lice found in the mass grave had DNA of *Bartonella*, suggesting that *Bartonella* caused a significant percentage of the deaths of these soldiers.

#### References:

1. Holmes, AH, et al. *Bartonella henselae* endocarditis in an immunocompetent adult. Clin Infect Dis, 21: 1004-1007, 1995.
2. Raoult, D., et al. Diagnosis of 22 new cases of *Bartonella* endocarditis. Ann Intern Med, 125: 646-652, 1996.
3. Ridder, GJ, et al. Spectrum and management of deep neck space infections: an 8-year experience of 234 cases. Otolaryngol. Head Neck Surg 133:709-714, 2005
4. Reynolds, MG, et al. Epidemiology of cat-scratch disease hospitalizations among children in the United States. Pediatr Infect Dis J 24:700-704, 2005.
5. Valerio, CR, et al. Bacterial 16S ribosomal DNA in house dust mite cultures. J. Allergy Clin Immunol 116:1296-1300, 2005.
6. La, VD, et al. *Bartonella quintana* in domestic cat. Emerg Infect Dis 11:1287-1289, 2005.
7. Raoult, D., et al. Evidence for louse-transmitted diseases in soldiers of Napoleon's Grand Army in Vilnius. J. Infect. Dis. 193:1120-1120, 2006.
8. Alsmark, CM, et al. The louse-borne human pathogen *Bartonella quintana* is genomic derivative of the zoonotic agent *Bartonella henselae*. Proc Natl Acad. Sci. 101: 26, 9716-9721, 2004.