



# NATIONAL VETERINARY LABORATORY

P.O. Box 239, 1Tice Road  
Franklin Lakes, NJ 07417  
877-NVL-LABS (877-685-5227)  
www.natvetlab.com

## NEWSLETTER

# Do *Bartonella* Cause Disease in Cats? II. Evidence from Pet Cats<sup>©</sup>

Evelyn E. Zuckerman, Editor

Spring 2010

Vol. 9, Number 2

### In This Issue:

In the spring 2010 issue of the NVL Newsletter we will continue to present published evidence that *Bartonella* do, in fact, cause inflammatory diseases in pet cats. Our last newsletter reviewed studies of experimentally-induced *Bartonella* diseases in cats and we will now review publications that document the same in pet cats.

### Conclusion:

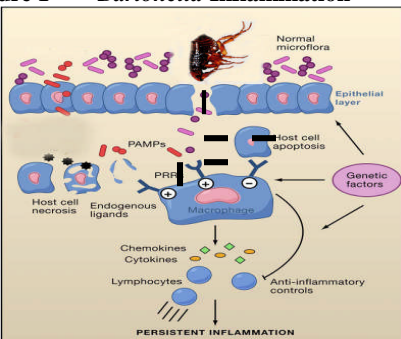
#### *Bartonella* cause disease in pet cats:

1. *Bartonella* induce inflammatory diseases after experimental inoculation.
2. Koch's Postulates have been fulfilled.
3. *Bartonella* cause inflammatory diseases in pet cats.
4. *Bartonella* infection in pet cats can be eliminated by antibiotic therapy and can be confirmed by a post therapy comparative antibody titer reduction test.

### *Bartonella* Pathogenesis:

*Bartonella* stick or clump together in tissues and stick to, and penetrate, RBCs, macrophages, and capillary endothelial cells. Pili, hair-like structures found on the bacteria's surface, and a protein called deformin, are responsible for the sticky properties.<sup>1</sup> The ability to adhere to many cell types leads to the wide and varied tissue pathogenesis observed in cats, dogs, and people. In addition, *Bartonella* stimulate macrophages and other cells to produce cytokines which orchestrate the inflammatory process (Figure 1).

Figure 1 *Bartonella* Inflammation



**Legend:** The black rods (--) represent *Bartonella* in the tissues. The bacteria induce an outpouring of inflammatory cytokines which recruit inflammatory cells such as lymphocytes, plasma cells, and macrophages. Adapted from reference 2.

### Publications of *Bartonella* Diseases in Pet Cats:

**Does coinfection of *Bartonella henselae* and FIV induce clinical disorders in cats?** Ueno, H., Hohdatsu, T., Muramatsu, Y., and Morita, C. *Microbiol Immunol* 40: 617-620, 1996.

This group of Japanese veterinarians found a causal association of *Bartonella henselae* with gingivitis and lymphadenopathy in a study of 170 pet cats. They found that *Bartonella henselae* may induce clinical disorders in pet cats from a comparison of the serological status for *Bartonella henselae* with the serological status for feline immunodeficiency virus (FIV) and several clinical diseases. Seropositivity for *Bartonella henselae* was not significantly different between FIV antibody-positive and -negative cats (18.4% vs. 16.0%). Clinical diseases were compared among four groups of cats distinguished by the reactivity of sera against *Bartonella henselae* and FIV. The incidence of lymphadenopathy was lower in only FIV antibody-positive cats (3.0%), but higher in *Bartonella henselae* antibody-positive cats (13.6%) and significantly higher in both *Bartonella henselae* and FIV antibody-positive cats (42.9%) compared with the incidence of lymphadenopathy in cats which were negative for both antibodies (5.5%). The same relationship was also observed for the incidence of gingivitis among the 4 cat groups, suggesting that coinfection of *Bartonella henselae* and FIV may be associated with gingivitis and lymphadenopathy in cats.

**Seroprevalence of *Bartonella henselae* infection and correlation with disease status in cats in Switzerland.** Glaus, T., Hofmann-Lehmann, R., Greene, C., Glaus, B., Wolfensberger, C., and Lutz, H.: *J Clin Microbiol* 35:2883-2885, 1997.

The authors reported a low seroprevalence for *Bartonella henselae* in 728 cats living in Switzerland, which is not a geographic area known to be favorable for flea habitation, the major *Bartonella* vector. They found a seroprevalence of only 8.3% for all cats and did not find any significantly different prevalence between sick and healthy cats (9.2 versus 7.2%). However, in sick cats seropositive for *Bartonella henselae*, they found an increased frequency of stomatitis ( $P=0.0117$ ) and a variety of diseases of the kidneys and the urinary tract that were not further differentiated ( $P=0.0337$ ).

**Vegetative endocarditis in six cats.** Malik, R., Barrs, VR, Church, DB, Zahn, A, Allan, GS, Martin, P, Wigney, DI, and Love, DN. *J Feline Med Surg* 1:171-180, 1999.

This paper describes 6 cases of vegetative endocarditis in Australian cats. Two of the cases were caused by *Bartonella* species isolated from the blood. The first case occurred in a 9-year-old DSH cat with a history of chronic dermatitis. On presentation there was a loud systolic murmur, cardiomegaly, pleural effusion and dyspnea. Echocardiography demonstrated thickened aortic valves. Despite therapy, the cat died of heart failure and the owners refused a necropsy. The second case occurred in a six year-old Persian cat who presented with severe dyspnea, hypertrophic cardiomegaly and pericardial effusion. The cat died 11 months later and necropsy revealed vegetative lesions on the aortic and mitral valves. Even though *Bartonella* were cultured from the blood of these 2 cats, the authors did not attempt to identify *Bartonella* in the vegetative valvular lesions.

**Seroprevalence of *Bartonella*-infection in healthy and diseased cats in the United States and Caribbean: Evidence for *Bartonella*-induced diseases in cats.** Hardy, WD, Jr., Zuckerman, E, Corbishley, J. *Internat. Conf. Amer. Society for Rickettsiology*, Big Sky, MT, August 17-22, 2001. In 2001, we reported the association of *Bartonella* with numerous inflammatory diseases in pet cats, oral and ocular disease being most common (Figures 2 & 3).

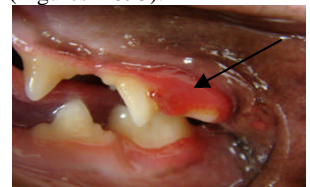

Figure 2. Early proliferative gingivitis in a young cat with no tartar. *Bartonella* seropositive +4 WB cat.

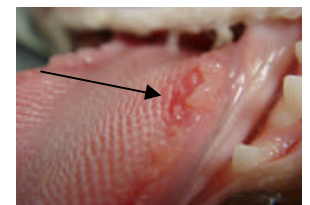
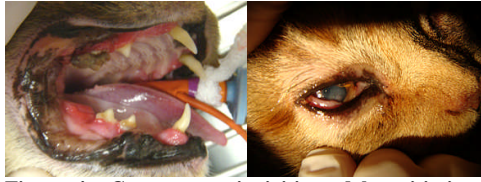

Figure 3. Oral ulcers on the tongue of a *Bartonella* seropositive +4 WB cat. Courtesy: Jan Corbishley, VT, Oradell Animal Hospital, Paramus, NJ.

We noted that the inflammatory diseases often occurred simultaneously in several tissues (Figure 4) such as the oral cavity and the eye or the respiratory tract and the skin.<sup>3</sup> Confirmation that *Bartonella* were the cause of these diseases was the significant clinical improvement after *Bartonella* antibiotic therapy and the corollary decrease in the *Bartonella* antibody titer.<sup>4,5</sup>



**Figure 4. Concurrent gingivitis and keratitis in a *Bartonella* seropositive +3 WB cat. Courtesy: Dr. Maria Berger, Cat Clinic North, Grand Rapids, MI.**

***Bartonella* spp antibodies and DNA in aqueous humor of cats.** Lappin, MR, Kordick, DL, and Breitschwerdt, EB. J Feline Med Surg 2:61-68, 2000. This group studied 49 client owned pet cats and 49 healthy shelter cats for the association of *Bartonella* and ocular infection. They detected *Bartonella* spp IgG (C value >1) in 7 of 49 pet cats with uveitis but in none of the healthy 49 shelter cats. They concluded: “*Bartonella* spp infect the eyes of some cats following natural exposure or experimental inoculation and may cause uveitis in some cats.”

**Editors Note: Our data show a very strong association of *Bartonella* and uveitis and other ocular inflammatory diseases including chorioretinitis, glaucoma and conjunctivitis.<sup>6,7</sup>**

**Fatal case of endocarditis associated with *Bartonella henselae* type I infection in a domestic cat.** Chomel, BB, Wey, AC, Kasten, RW, Stacy, BA, and Labelle, P. J Clin Microbiol 41:5337-5339, 2003.

This case occurred in an 8-year-old female spayed cat who presented with a grade IV/VI systolic heart murmur and an arrhythmia. Thoracic radiographs revealed severe cardiomegaly and an echocardiogram showed markedly thickened aortic valve leaflets. Blood culture at this time, and 1 month later, were negative even though there was high antibody titers to *Bartonella henselae* (1:4,096) and *Bartonella clarridgeiae* (1:8,192). The cat died due to cardiopulmonary arrest despite resuscitation attempts. Necropsy revealed *Bartonella henselae* Type I DNA and silver stain positive coccoid structures in endothelial cells of the damaged aortic valve.

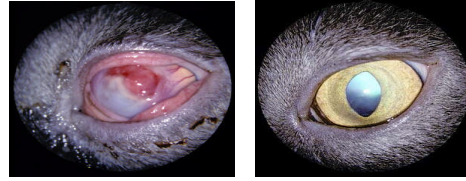
**Editors Note: This case demonstrates that *Bartonella* specific antibodies can be present even when the bacteria cannot be cultured from the blood.<sup>3</sup> It has been shown that *Bartonella* infected cats have intermittent bacteremia which may account for the inability to culture the bacteria from the blood of some antibody positive infected cats.<sup>8</sup>**

**A new etiological agent of feline ocular diseases.** Ketring, KL, Zuckerman, EE & Hardy, WD, Jr. *Bartonella*: JAAHA, 40:6-12, 2004.

In 2004, Dr. Kerry Ketring and our laboratory published the association of *Bartonella* with feline ocular diseases. We studied 1,649 cases of ocular inflammation in pet cats, many seen by Dr. Ketring, a Diplomat, ACVO. We reported the

association in: uveitis 145/251 58%, conjunctivitis 704/1,375 51%, chorioretinitis 6/7 86%, keratitis 3/4 75% and corneal ulcer 7/12 58%. Thus 872/1,649 53% of cats with ocular inflammatory diseases were seropositive for *Bartonella* by western blot. Notably, in most of these cats, there was marked clinical improvement or total resolution of their disease with azithromycin antibiotic therapy (Figure 5).

**Figure 5. Corneal Ulcer: Before and after therapy<sup>6</sup>**



**Recurrent osteomyelitis in a cat due to infection with *Bartonella vinsonii* subsp. *berkhoffii* genotype II.** Varanat, M, Travis, A, Lee, W, Maggi, RG, Bissett, SA, Linder, KE, and Breitschwerdt, EB. J Vet Intern Med 23:1273-1277, 2009.

This is a case report of a 4-year-old spayed-female DSH cat who originated from a North Carolina shelter as a kitten. There was a nonpainful swelling of the left metatarsal region which showed lysis of the 1<sup>st</sup> metatarsal bone by radiographs. The left metatarsophalangeal joint was disarticulated and the digit was removed. The disease recurred a year later and at that time direct *Bartonella* PCR from the blood was negative whereas *Bartonella* DNA was amplified from blood culture media even though there was no bacterial growth and the *Bartonella vinsonii* subsp. *berkhoffii* antibody titer was positive at 1:128. The cat was treated for 3 months with azithromycin at 10 mg/kg PO q48h. The cat's condition improved and 6 months after therapy no *Bartonella* were cultured from the blood and the antibody titer decreased to negative.

**Editors Note: There are 7 *Bartonella* species that infect pet cats. As we have reported for 10 years, *Bartonella* infections can be eliminated by azithromycin antibiotic therapy and confirmed by a post therapy titer decrease.<sup>4,5</sup>**

**Association between *Bartonella* infection and disease in pet cats.** Sykes, JE, Westropp, JL, Kasten, RW, and Chomel, BB. Abstract A1. Intern Conf on *Bartonella* as Medical & Veterinary Pathogens, Chester, UK, June 2009. In this study, 299 cats were evaluated for *Bartonella* associated diseases. They found a statistical association with *Bartonella* isolation and stomatitis (P=0.003).

## “Negative” Publications of *Bartonella* Associated Diseases

There have been several publications reporting no association of *Bartonella* with diseases in pet cats.<sup>9-11</sup> Most of the studies compared the difference between healthy cats and cats with various diseases and used statistical analysis to show no association. Similar conclusions had been made for years for the lack of disease-association of *Helicobacter pylori* and human gastric ulcers and gastric cancer. Eventually these negative studies were proven incorrect and the elucidation of the pathogenesis of *H. pylori* led to the 2005 Nobel Prize in Medicine awarded to Barry J. Marshall and J. Robin Warren. The press release of the Nobel Assembly stated: “Many diseases in humans such as Crohn’s disease, ulcerative colitis, rheumatoid arthritis, and

atherosclerosis are due to chronic inflammation. The discovery of *Helicobacter pylori* has led to an increased understanding of the connection between chronic infection, inflammation, and cancer.” *Bartonella* infection in cats leads to chronic inflammatory diseases similar to those of *H. pylori*.

## P-Value Statistics- “Negative Studies”

The misuse of “statistical significance” in studies using inadequate numbers has been argued in the scientific literature for some time.<sup>12,13</sup> A relevant article was published in the British Medical Journal in 1995 by Altman and Bland entitled: **Absence of evidence in not evidence of absence.** The authors pointed out the common misuse of the “P-value” in publications, especially when the sample size studied was relatively small. Unlike those studies, we have tested more than 243,000 pet cats for *Bartonella* and found an association with inflammatory conditions in many tissues of pet cats.

## References:

- Xu, YH, Lu, ZY & Ihler, GM. Purification of deformin, an extracellular protein synthesized by *Bartonella bacilliformis* which causes deformation of erythrocyte membranes. Biochim Biophys Acta 1234: 173-83, 1995.
- Karin, M, Lawrence, T, Nizet, V. Innate immunity gone awry: linking microbial infections to chronic inflammation and cancer. Cell 124:823-835, 2006.
- Hardy, WD, Jr., Zuckerman, E, Corbishley, J. Seroprevalence of *Bartonella*-infection in healthy and diseased cats in the United States and Caribbean: Evidence for *Bartonella*-induced diseases in cats. International Conference of the American Society for Rickettsiology, Big Sky, MT, August 17-22, 2001.
- Hardy, WD, Jr., Zuckerman, EE, Corbishley, J, et al. Efficacy of high dose, long duration Doxycycline or Azithromycin treatment for *Bartonella* infections in pet cats. International Conference of the American Society for Rickettsiology, Big Sky, Montana, August, 2001.
- Hardy, W.D., JR., Zuckerman, E.E., Corbishley, J, et al. Successful therapy of *Bartonella henselae* bacteremic healthy pet cats. Annual Meeting, Infectious Disease Society of America, New Orleans, Sept., 1996.
- Ketring, KL, Zuckerman, EE & Hardy, WD, Jr. *Bartonella*: A new etiological agent of feline ocular diseases. JAAHA, 40:6-12, 2004.
- Hardy, WD, Jr., Zuckerman, E, Ketring, K, Fischer, C, Mineo, M. *Bartonella*-induced ocular inflammatory diseases of cats. Upsala J Med Sci, Suppl. 57: 37, 2005.
- Kordick DL et al.: Clinical and pathologic evaluation of chronic *Bartonella henselae* or *Bartonella clarridgeiae* infection in cats. J Clin Microbiol 37:1536-1547, 1999.
- Pearce LK, Radecki, SV, Brewer, M, and Lappin, MR. Prevalence of *Bartonella henselae* antibodies in serum of cats with and without clinical signs of central nervous system disease. J Feline Med Surg 8:315-320, 2006.
- Berryessa, NA, Johnson, LR, Kasten, RW, and Chomel, BB. Microbial culture of blood samples and serological testing for bartonellosis in cats with chronic rhinosinusitis. JAVMA 233:1084-1089, 2008.
- Quimby, JM, Elston, T, Hawley, J, Brewer, M, Miller, A, and Lappin, MR. Evaluation of the association of *Bartonella* species, feline herpesvirus 1, feline calicivirus, feline leukemia virus, and feline immunodeficiency virus with chronic feline gingivostomatitis. J Feline Med Surg 10:66-72, 2008.
- Rigby, AS. Statistical methods in epidemiology. I. Statistical errors in hypothesis testing. Disability and Rehabilitation 20:121-126, 1998.
- Altman, DG and Bland, JM. Absence of evidence is not evidence of absence. British Med J 311:485, 1995.

***Bartonella* references can be obtained at:**

[www.nlm.nih.gov/](http://www.nlm.nih.gov/)